Information and communication technology nel neuroimaging dell'addiction

OPPORTUNITA' E SVILUPPI FUTURI

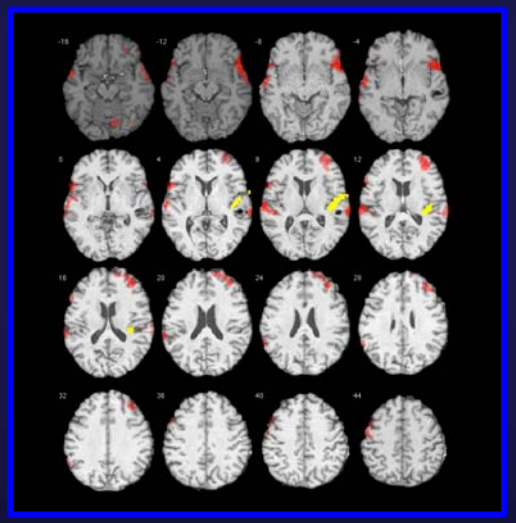

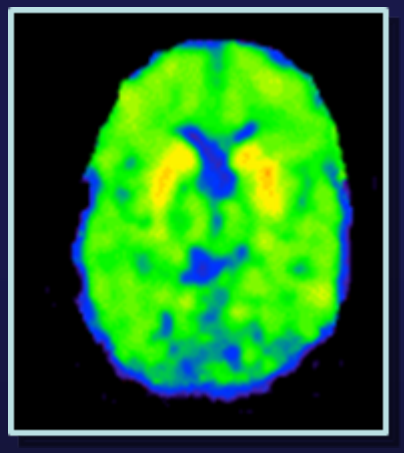

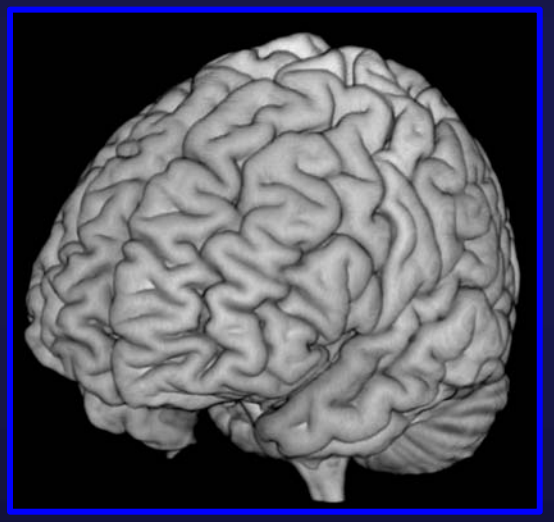

Giada Zoccatelli
Risonanza Magnetica
Servizio di Neuroradiologia
Verona

Franco Alessandrini
Risonanza Magnetica
Servizio di Neuroradiologia
Verona

MR Identification of White Matter Abnormalities in Multiple Sclerosis: A Comparison between 1.5 T and 4 T

Mark D. Keiper, Robert I. Grossman, Joshua A. Hirsch, Lizann Bolinger, Ingrid L. Ott, Lois J. Mannon, Curtis P. Langlotz, and Dennis L. [illegible]

AJNR Am J Neuroradiol 23:1553–1556, October 2002

Technical Note

Visualization of Microvascularity in Glioblastoma Multiforme With 8-T High-Spatial-Resolution MR Imaging

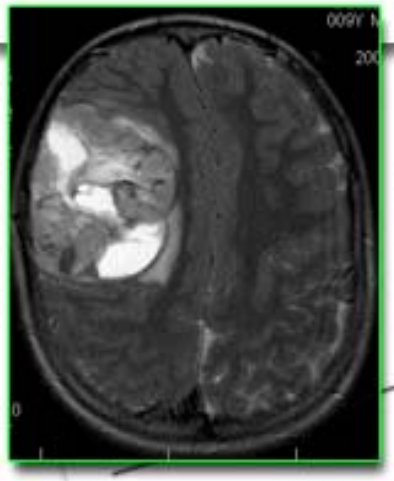

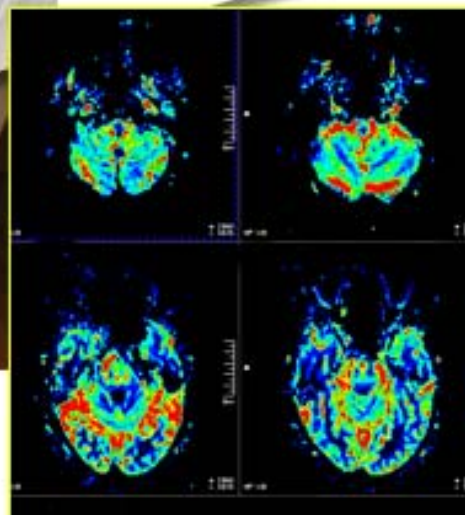

New frontiers in Radiology

RM @ alto campo *caratteristiche*

- Elevata risoluzione spaziale
- Elevata risoluzione temporale
- Elevato contrasto
- Elevata sensibilità
- ***Non invasività***
- ***Versatilità***

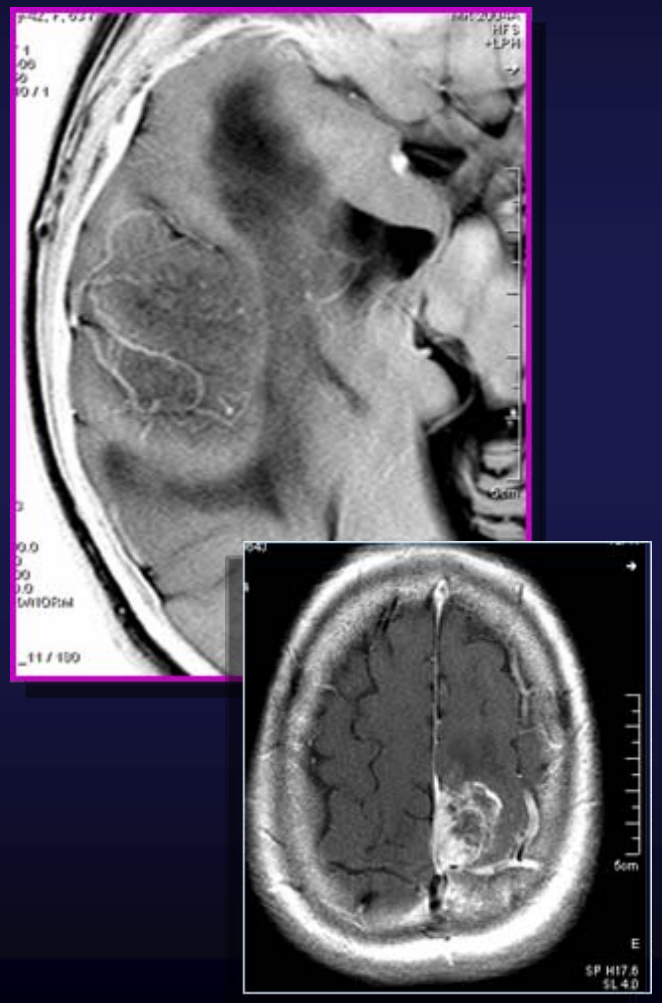

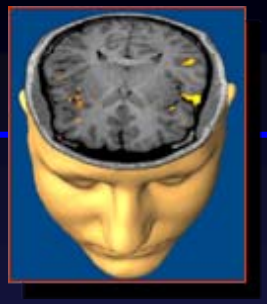

Risonanza Magnetica

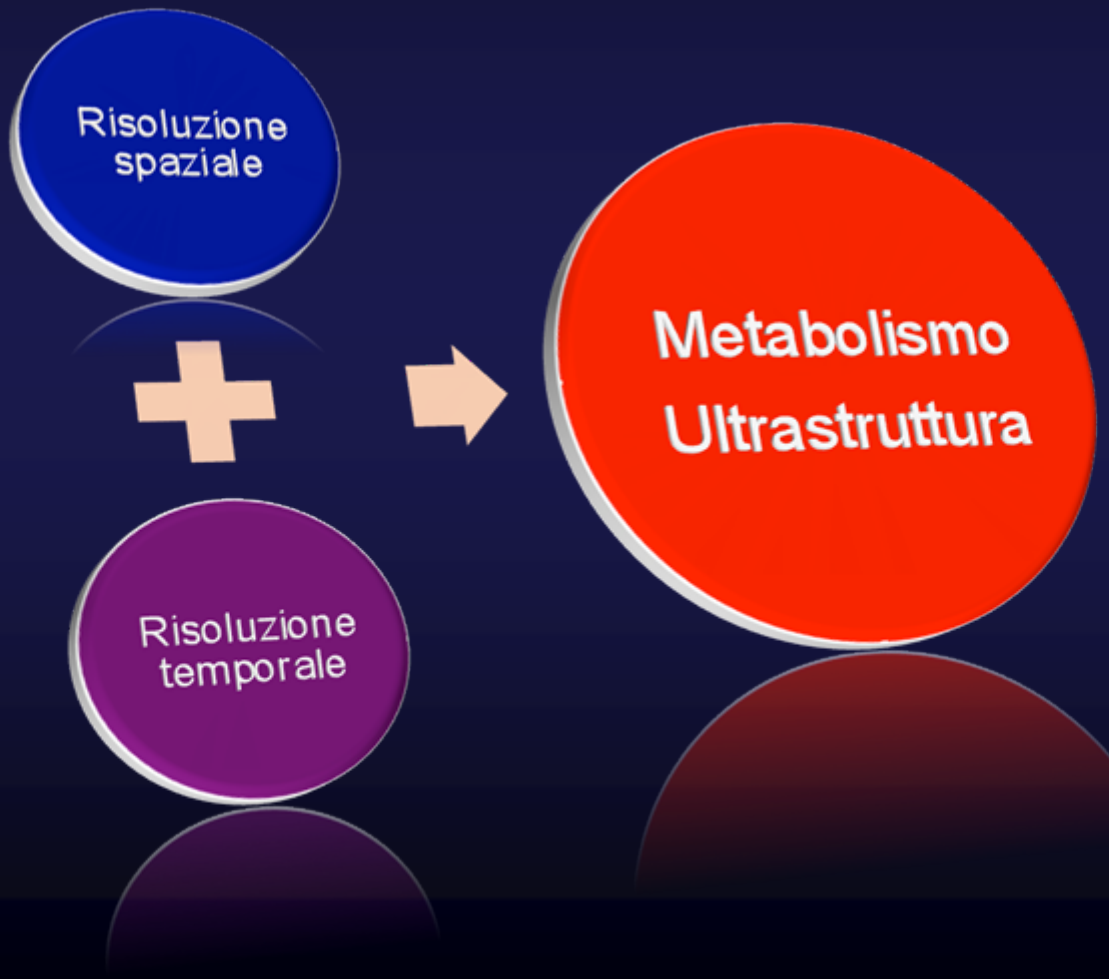

Evoluzione


RMN
RM alto campo
RM Convenzionale
Morfologia
Funzione
Ultrastruttura
Morfologia
(Funzione)

Tossicodipendenza

Overview

- Perfusione (PWI)
- Spettroscopia (MRS)
- Attivazione funzionale (*f* MRI)
- Spessore corticale
- Tensore di diffusione (DTI)

Neuroimaging

Perfusione (PWI)

- Identifica la presenza di vascolarizzazione neoplastica
- Indici di riferimento
- Consente distinguere tumori da lesioni pseudo-tumorali

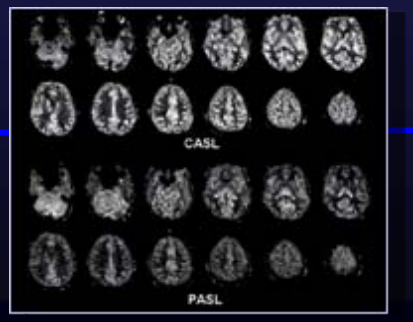

- ***rel* CBF**
- ***rel* CBV**
- TTP
- MTT

Perfusione (PWI)

1. CE - PWI (con mdc, in bolo)
2. PASL - CASL (senza mdc)

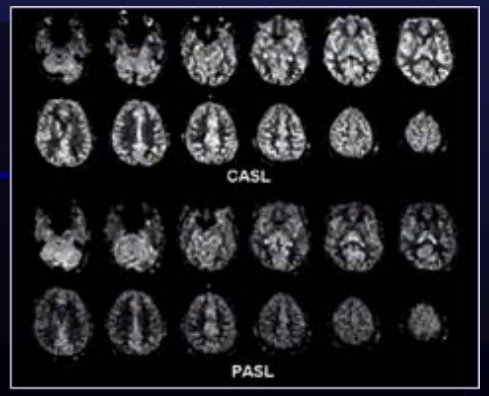

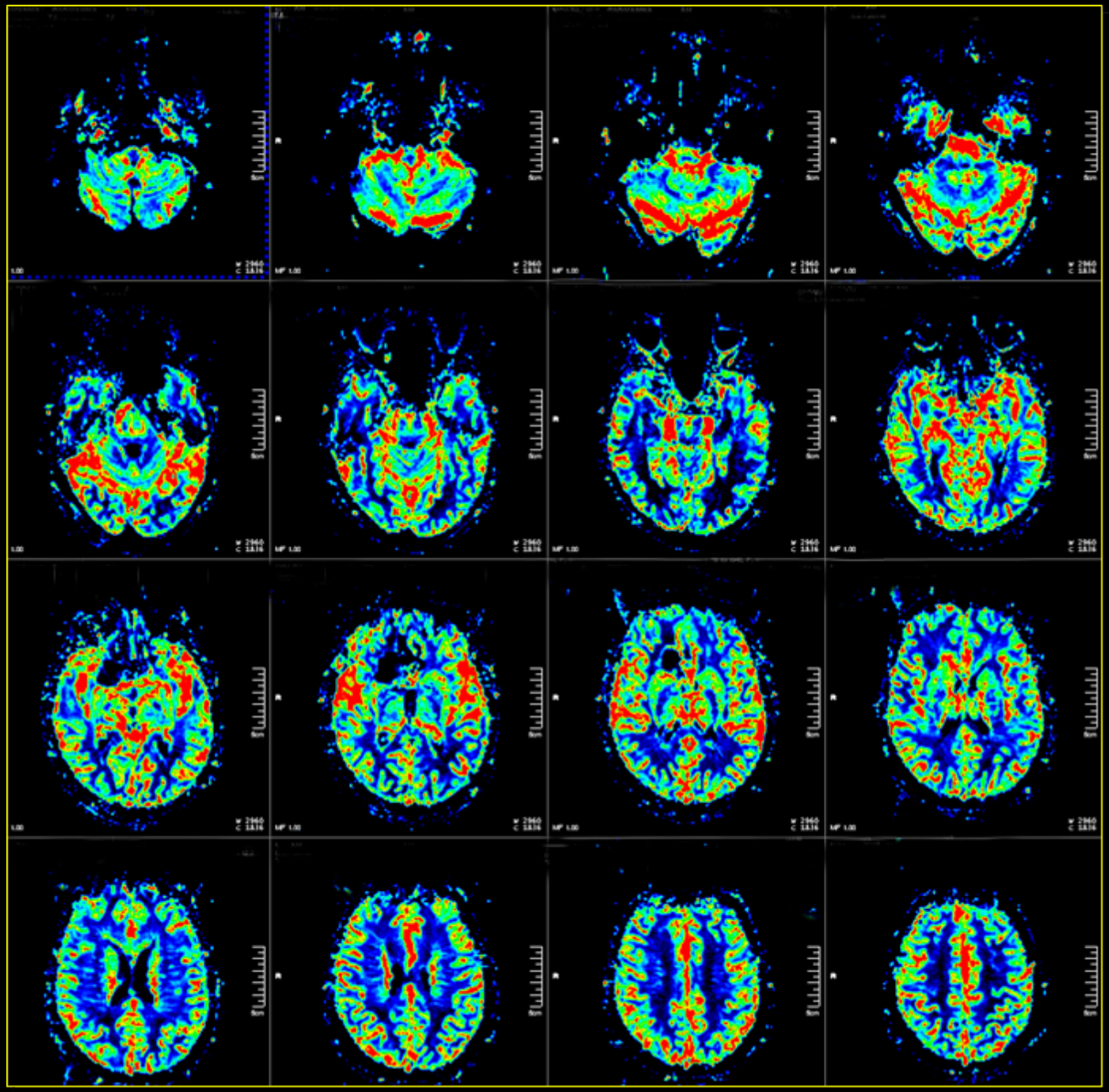
100%
20%

Perfusione

cASL/pASL

- "Work in progress"
- NON invasiva

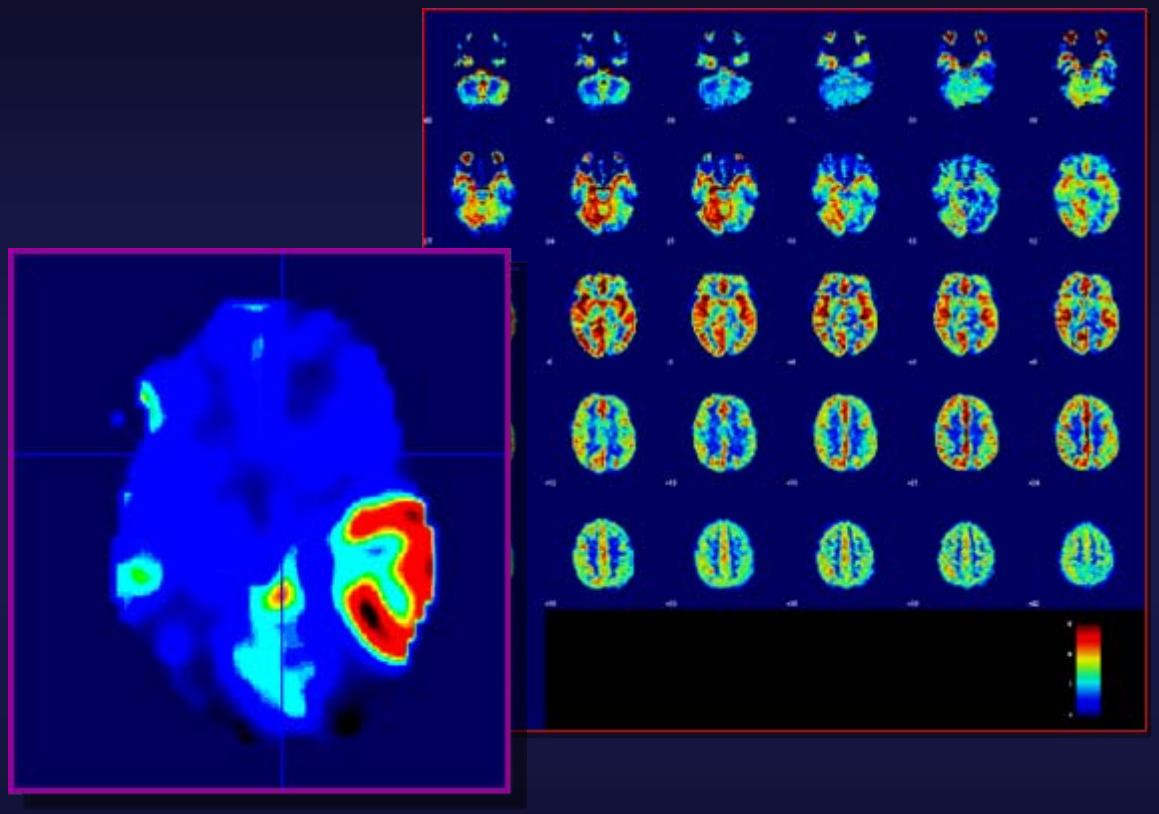

✓ I protoni legati alle molecole del sangue, "marcati" a livello del collo con impulsi di RF, vengono utilizzati come tracciante endogeno

✓Si valuta la perturbazione/variazione di segnale negli strati distali, quando i protoni "marcati" diffondono a livello encefalico

Cerebral Blood Flow (CBF):

PET and Arterial Spin Labeling (ASL)

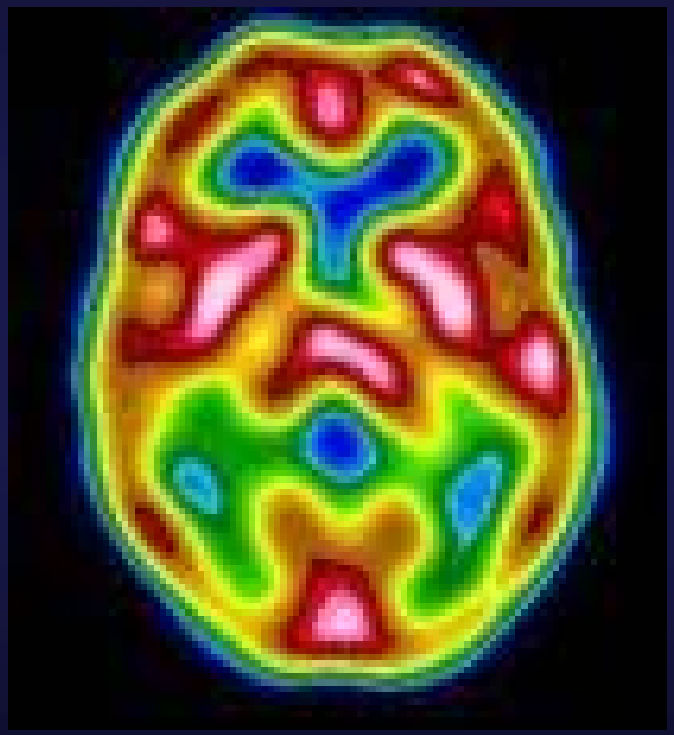

Ye, F.Q et al. 2000. *Magn Reson. Med.* 44:450-456.

PET: $H_2{}^{15}O$

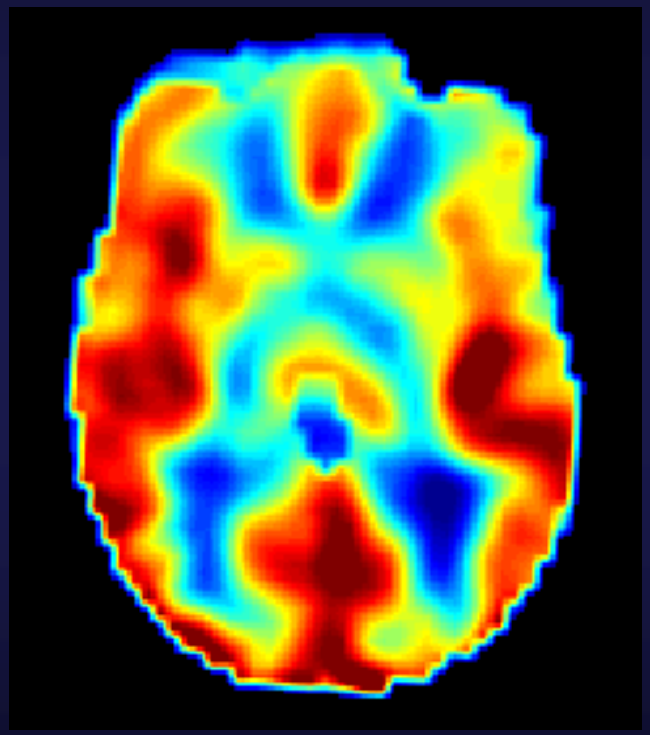

MR: ASL

Correlazione dei risultati di perfusione MRI (DSC e ASL) con dati PET

PWI senza mdc *applicazioni cliniche*

- Valutazione parametri di perfusione dei ***tumori***, (CBV correla con il grading)
- Caratterizzazione e definizione di tessuto ipoperfuso/ischemico nell'***ischemia cerebrale***
- Valutazione dei parametri perfusivi in ***e.s.a.***
- . . . . **TOSSICODIPENDENZA**

PWI

applicazioni cliniche

perfusione baseline

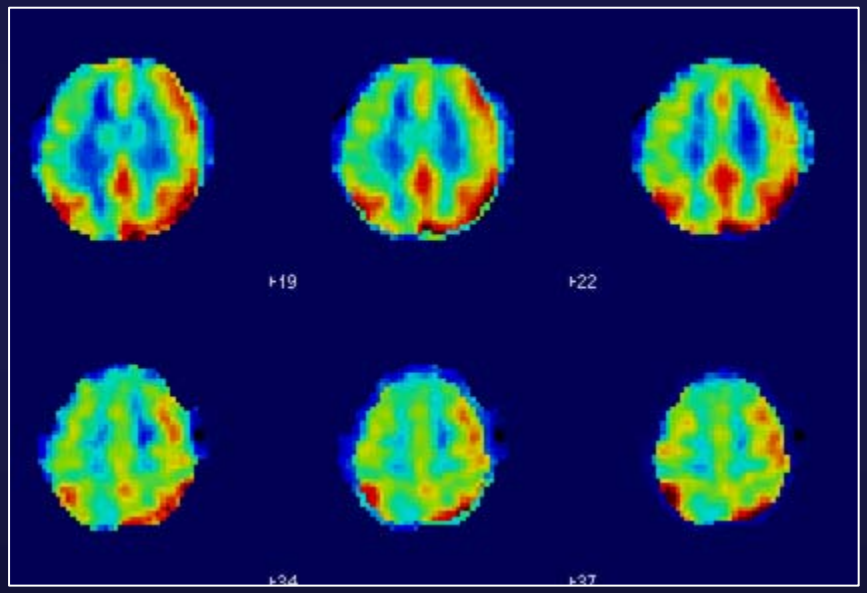

perfusione craving

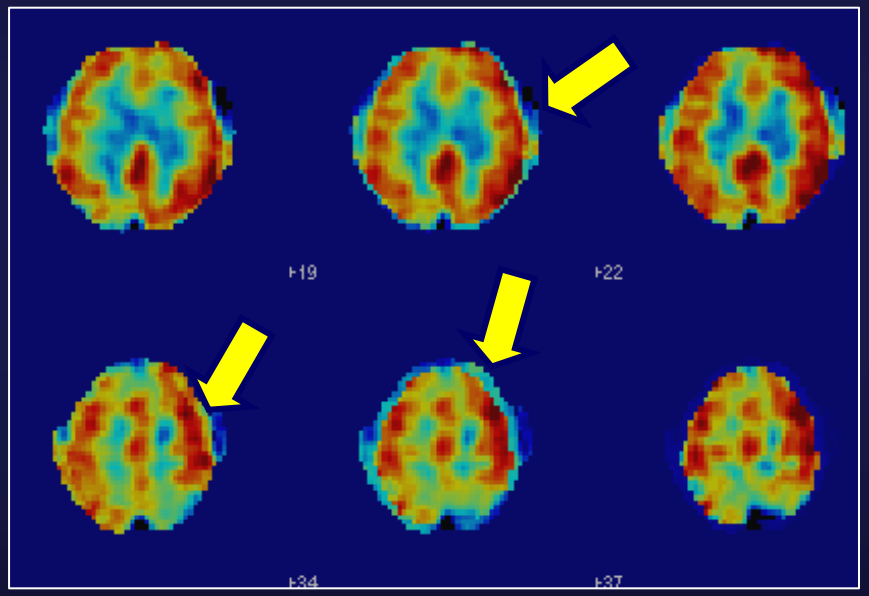

aumento del flusso sanguigno cerebrale

Spettroscopia (MRS)

Single voxel (SVS)
Multivoxel (CSI, 2D-3D)

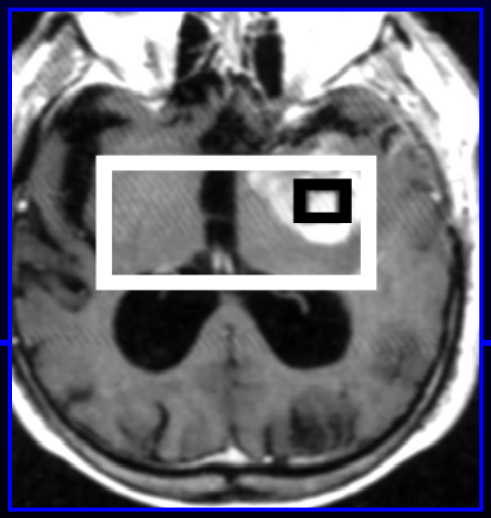

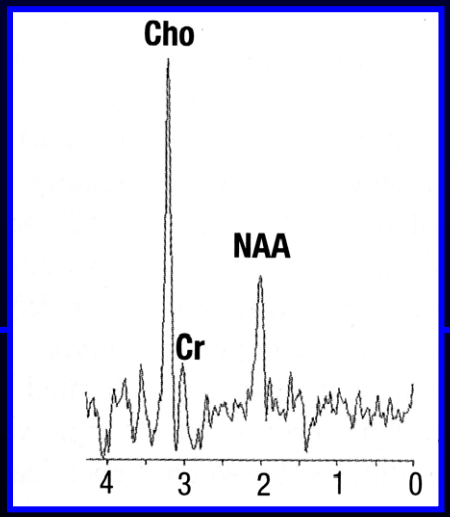

Neuroimaging

Spettroscopia RM

- Metodica fondamentale per:
  - ***analisi dell'interazione molecolare***
  - ***identificazione dei composti chimici***
- Non invasiva
- Non morfologia ma ***metabolismo***
- ***In vivo***

Neuroimaging





RM morfologica

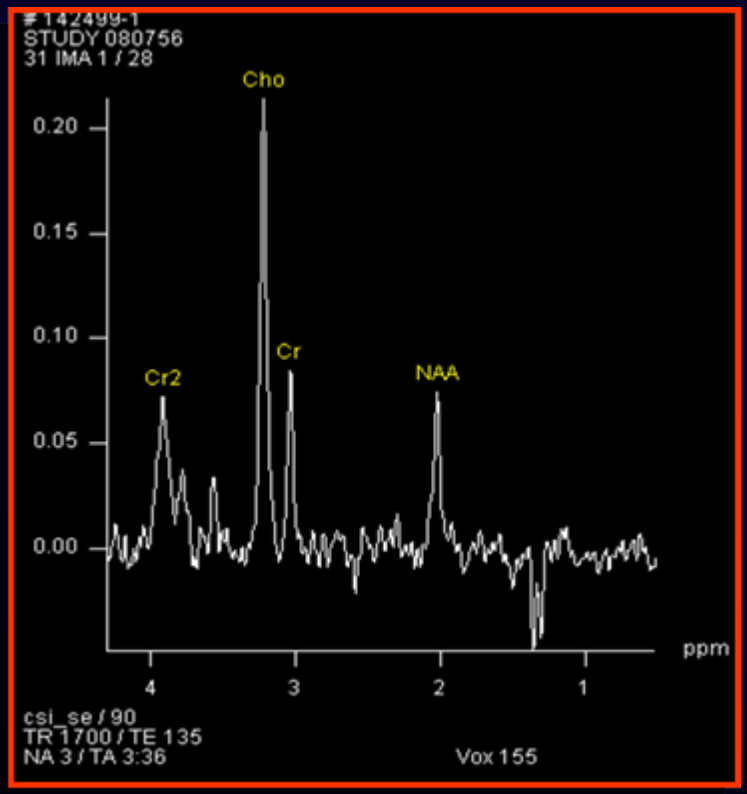

RM Spettroscopia

METABOLITI

TE = 30 msec

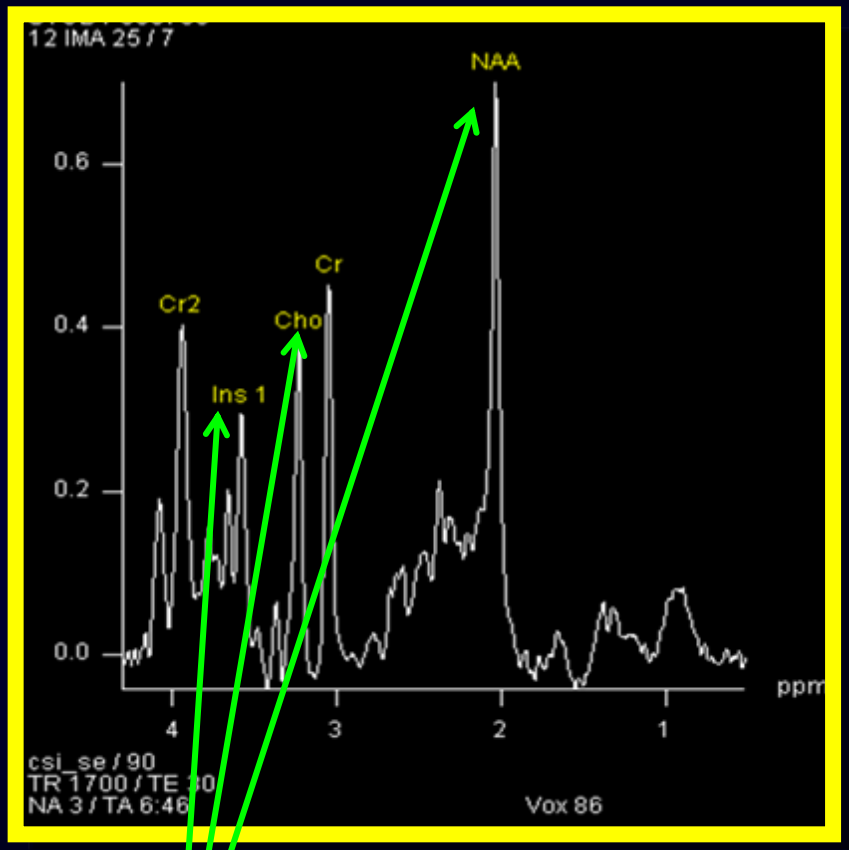

TE = 135 msec

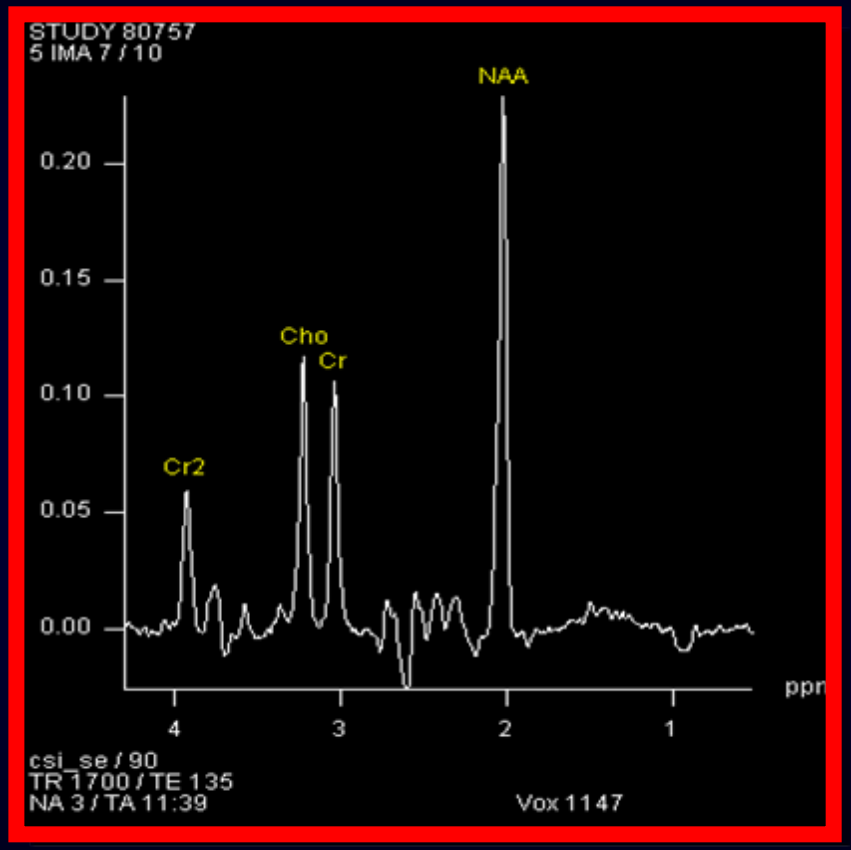

"picchi"

"Spettri"

METABOLITI

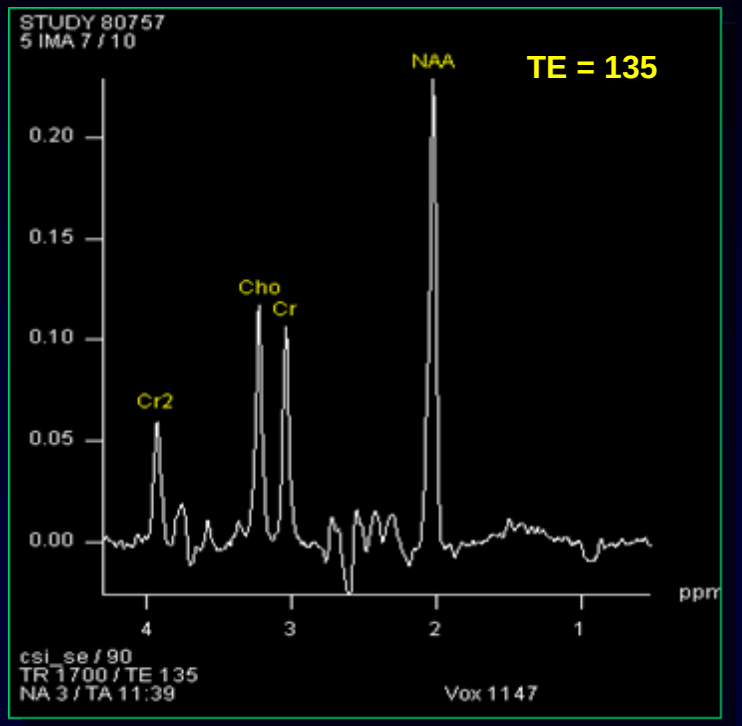

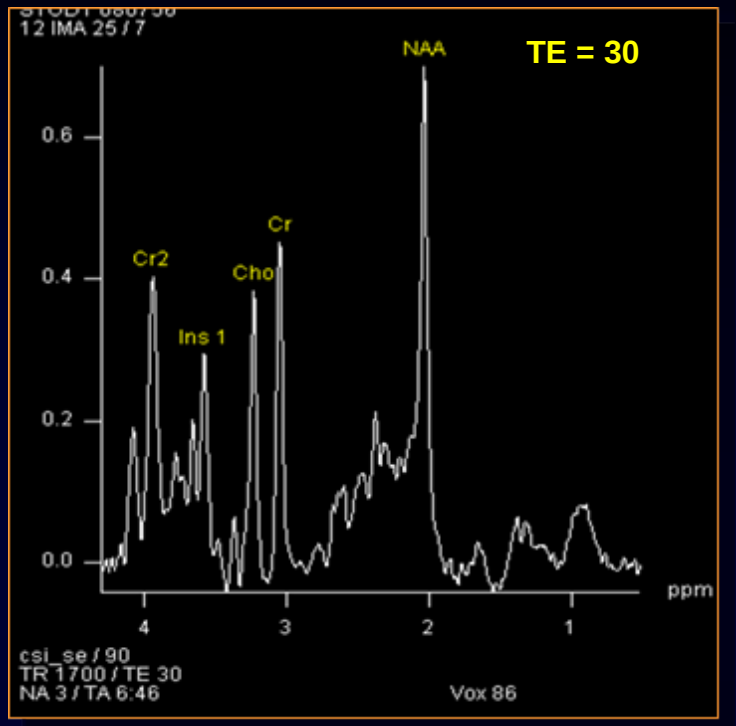

NAA: N-Acetil-Aspartato

Cho: Colina

Cr: Creatina

Ins: Mio-Inositolo

Lipidi

Lattato

METABOLITI

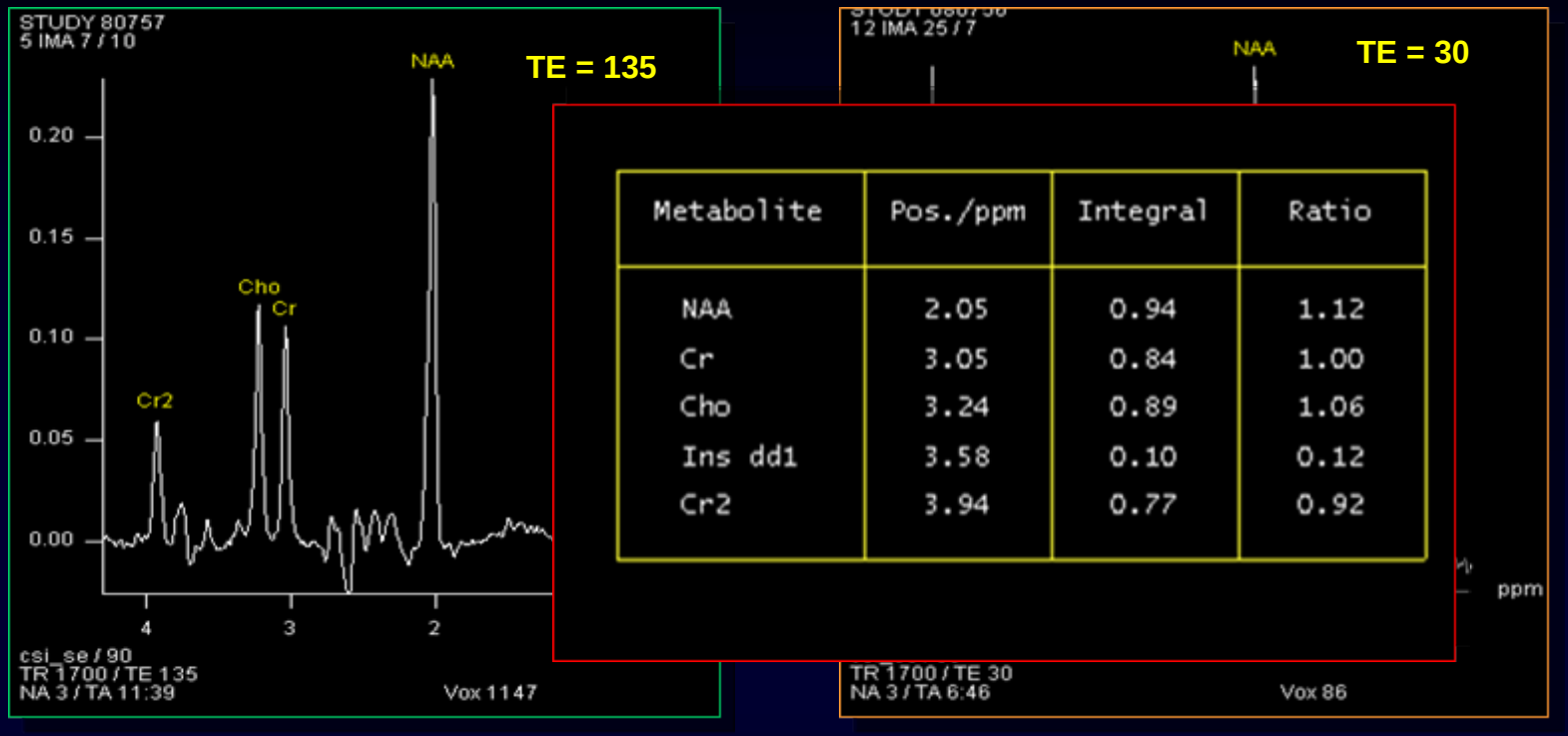

Metabolite	Pos./ppm	Integral	Ratio
NAA	2.05	0.94	1.12
Cr	3.05	0.84	1.00
Cho	3.24	0.89	1.06
Ins dd1	3.58	0.10	0.12
Cr2	3.94	0.77	0.92

- Analisi qualitativa

  riconoscimento dei picchi
- Analisi quantitativa (“ratio”)

  Cho/Cr, NAA/Cr, Ins/Cr, Cho/NAA…

Spettroscopia RM

Multi Voxel (CSI)

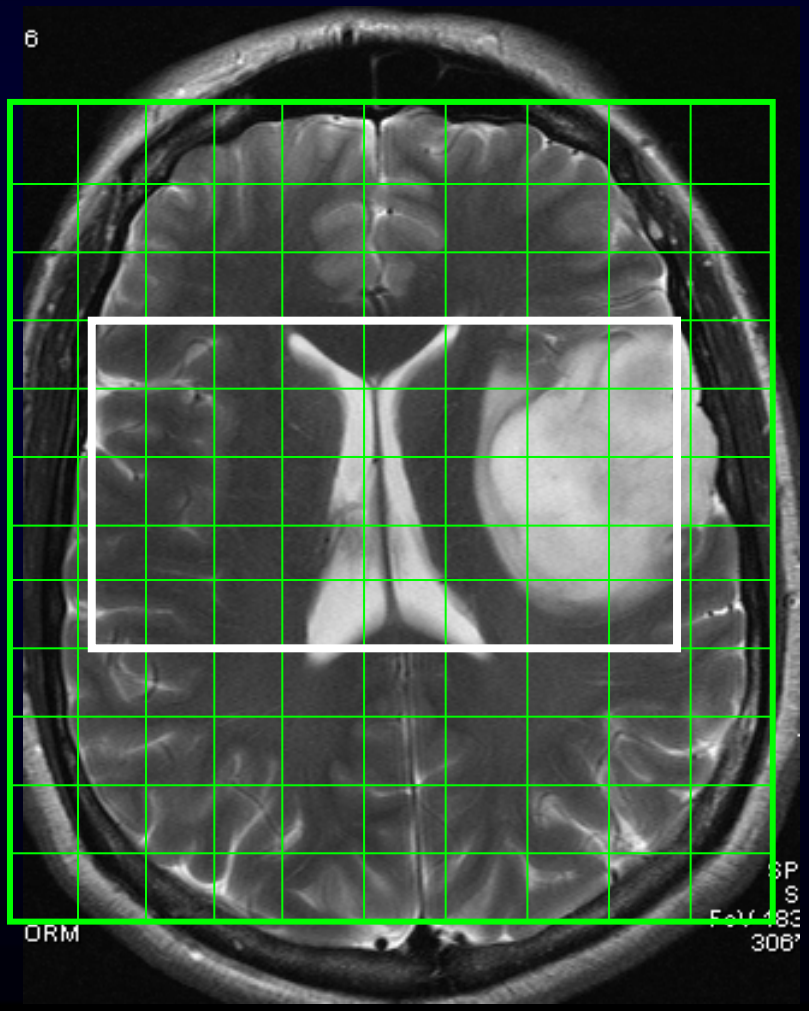

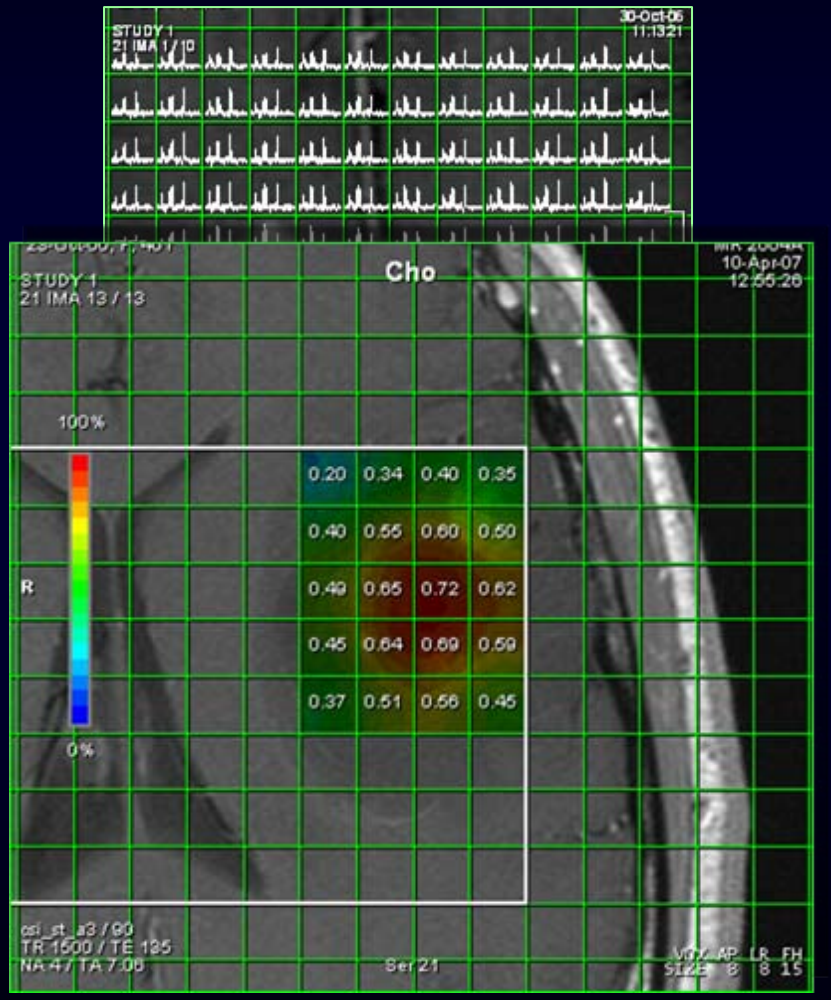

Mappa metaboliti

Spettroscopia RM

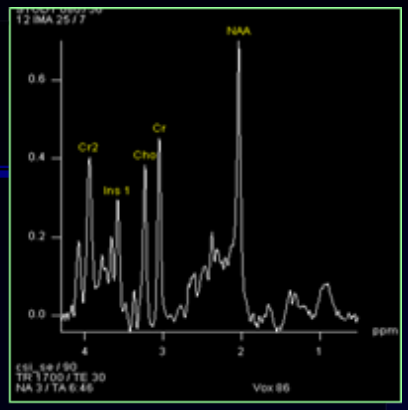

Indicazioni

- Tumori
- Patologia infiammatoria
- Epilessia
- Patologia infettiva
- Patologia degenerativa e metabolica
- ***Dipendenze***

SPETTROSCOPIA

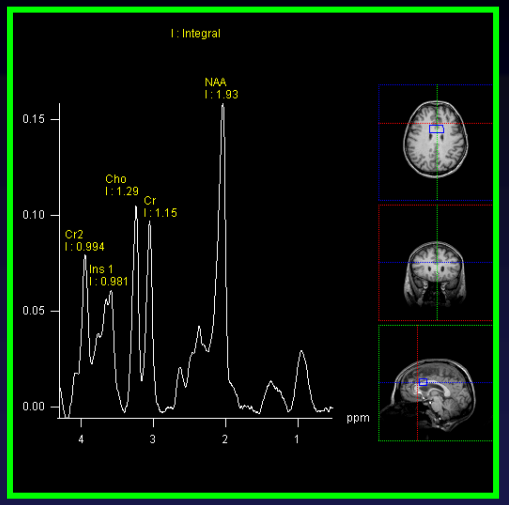

- ✓ Metaboliti cerebrali
  NAA, Cho, Cr, Ins, Lat, Lip, etc

- ✓ *Tossicodipendenza e Glutammato*

Eroina inalata

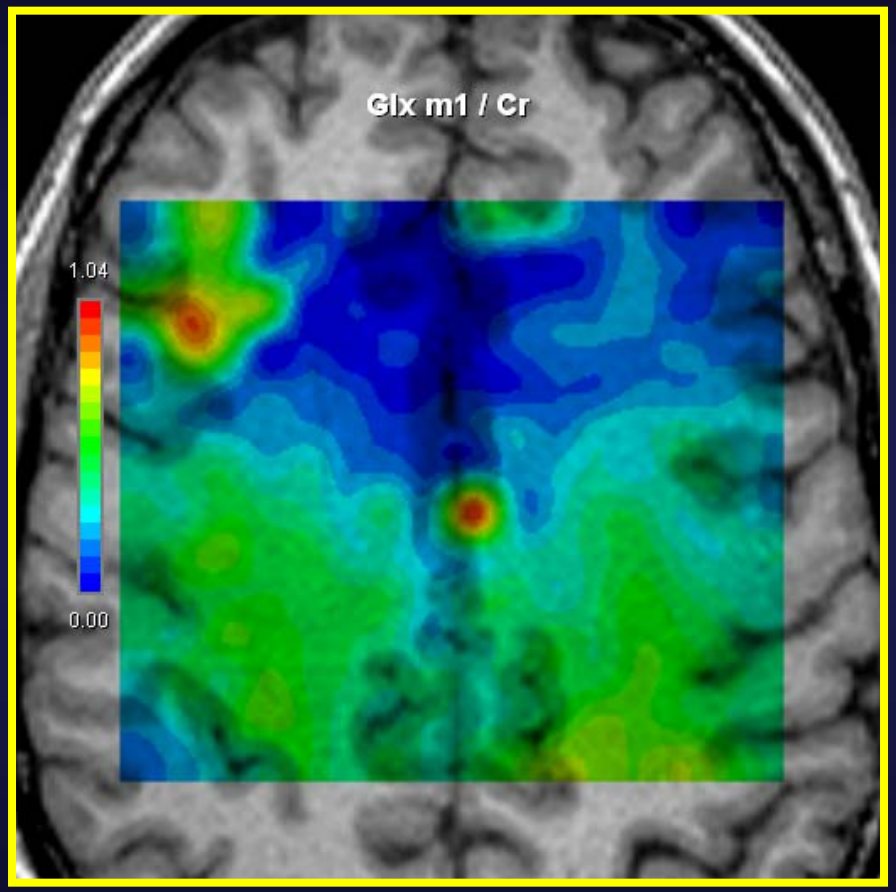

Volontario sano

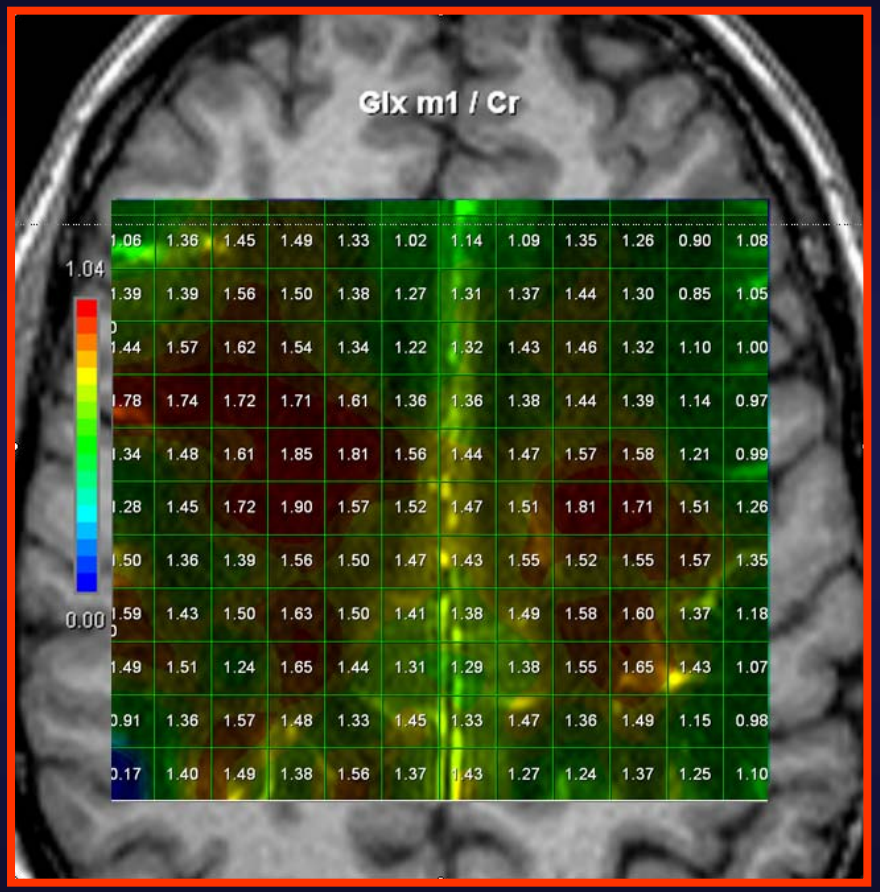

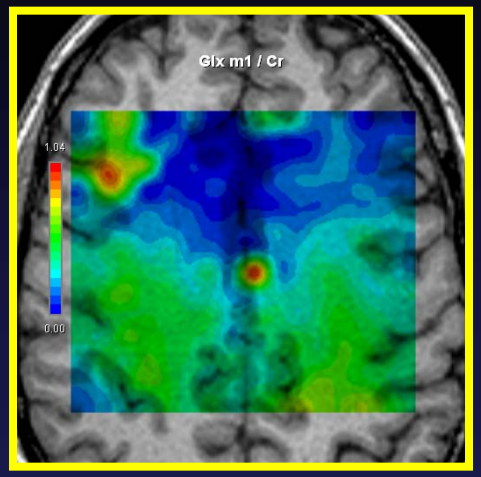

MRS

tossicodipendenza

- Riduzione del Glutammato nel cingolo anteriore
- Forme croniche
- Correlato con danno strutturale
- Dato quantitativo
- Mappe CSI

DAL SEGNALE RM…

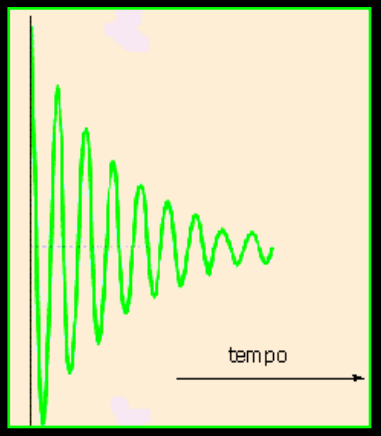

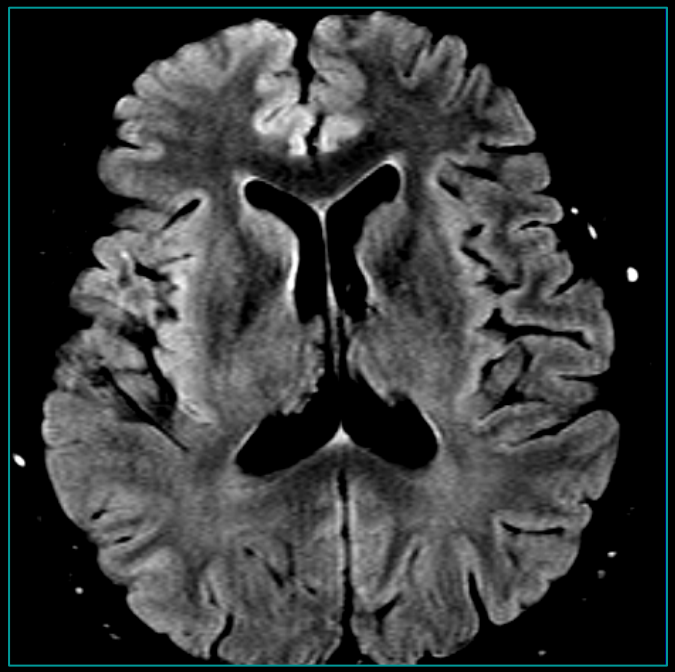

..convenzionale

…ALL'IMMAGINE RM

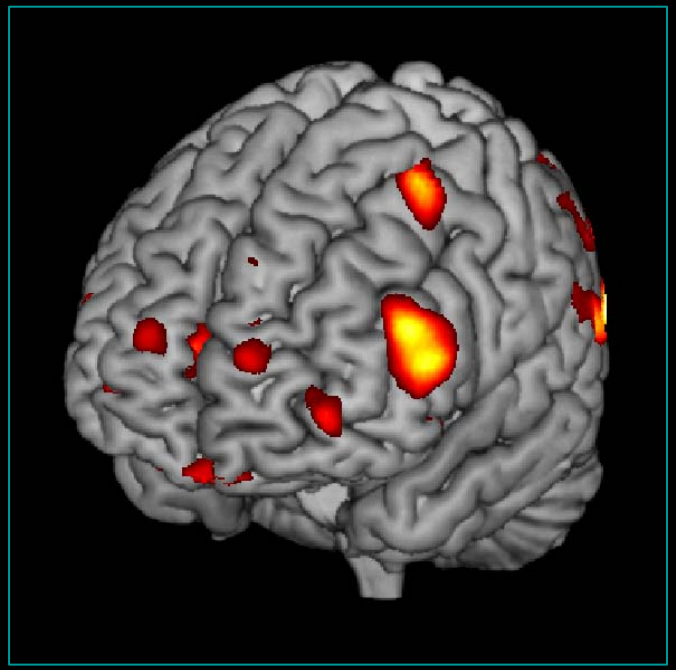

..funzionale

*f*MRI

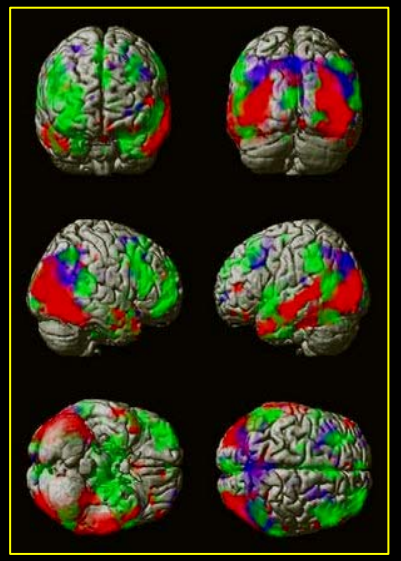

- analisi della funzione cerebrale
- non invasiva
- ottima risoluzione spaziale e temporale
- alta sensibilità



Fisiologia

Segnale BOLD

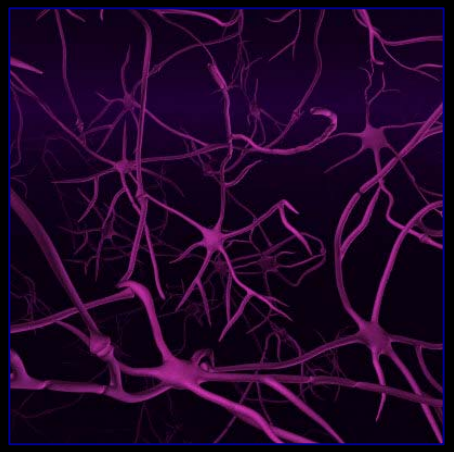

Scarica neuronale

➡ modificazioni del flusso capillare

➡ modif. stato di ossigenazione dei g. rossi

Ossi-emoglobina HbO_2 → desossi-emoglobina dHb

⬇

Variazioni di segnale locale alla base delle immagini di RM funzionale

ESAME DI RM

funzionale



- Definire il protocollo sperimentale

  - funzione cognitiva d’interesse (motoria, verbale, visiva..)

  - modalità sensoriale appropriata (visiva, uditiva, tattile..)

- Istruire il paziente

- Eseguire l’esame RM

Elaborazione dei dati

MRI

- Attivazione funzionale
- Spessore corticale
- Tensore di diffusione

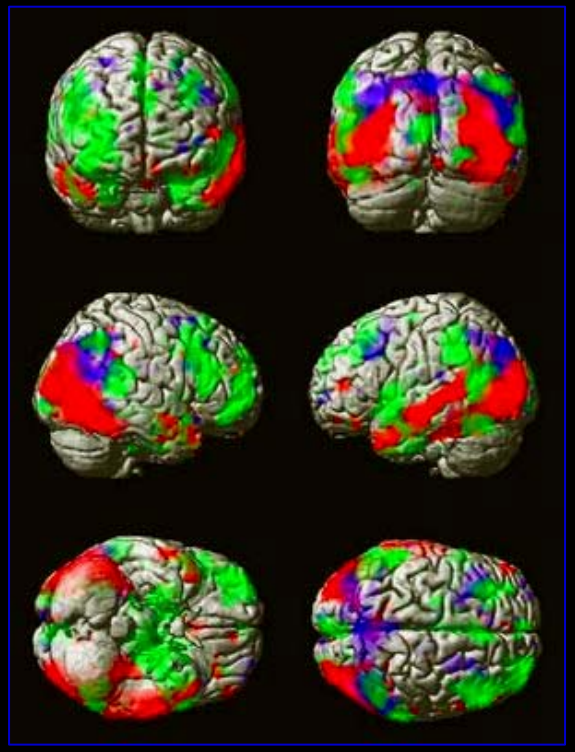

RM funzionale



- Software dedicati all'analisi dei dati RM:
  - ✓ **pre-processing**
    (correzione, filtraggio, allineamento)
  - ✓ **processing**
    (coregistrazione delle immagini, analisi statistica)

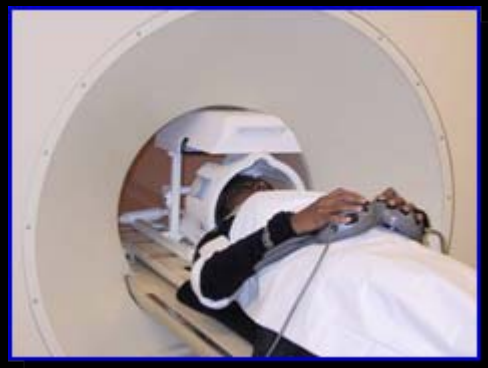

- buona compliance del paziente
- comprensione del compito

Attivazione funzionale

*f*MRI

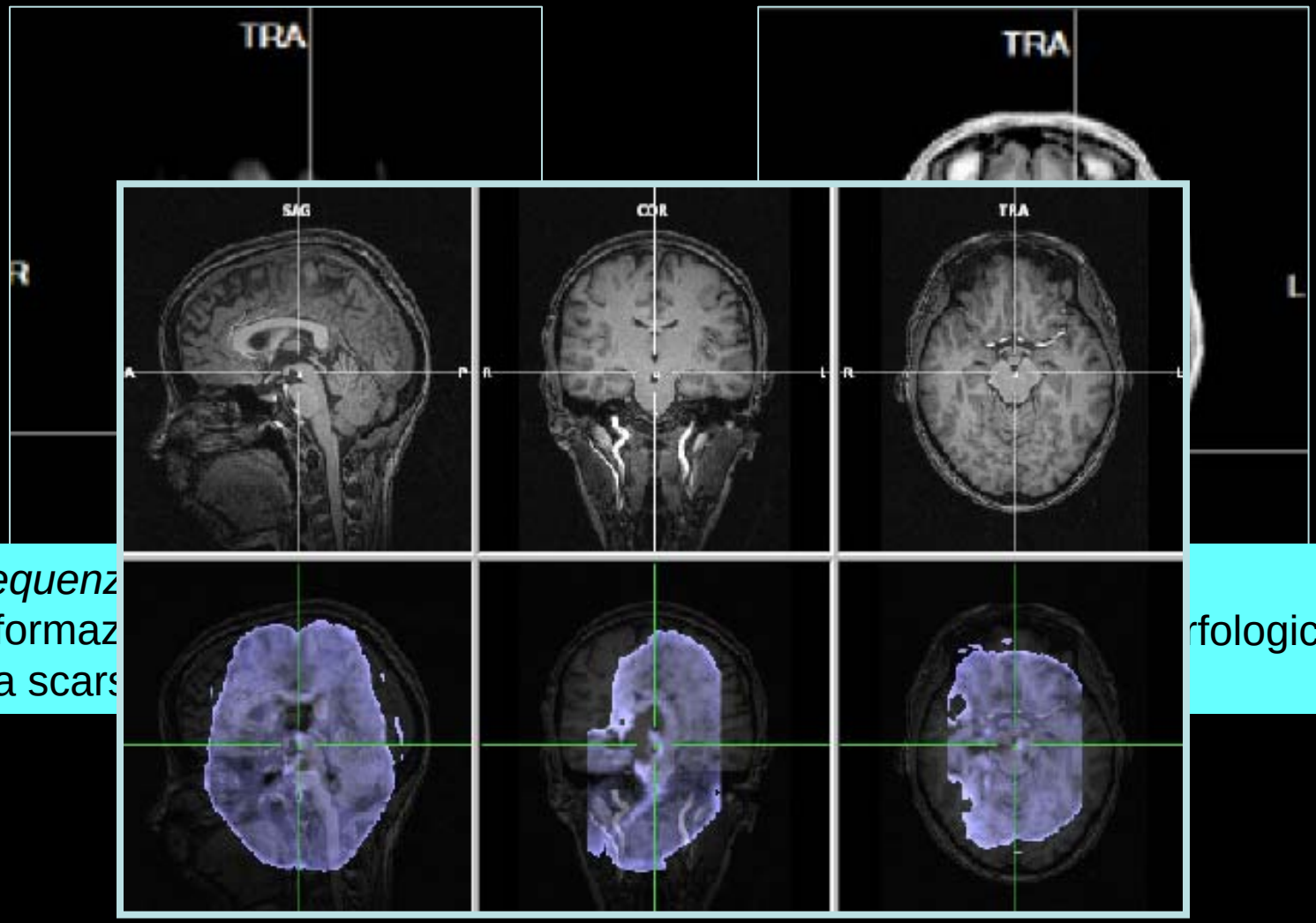

Sequenz
Informaz
ma scars

rfologica

Mappa di attivazione

- informazioni anatomiche
- informazioni emodinamiche
- corrispondenza paradigma

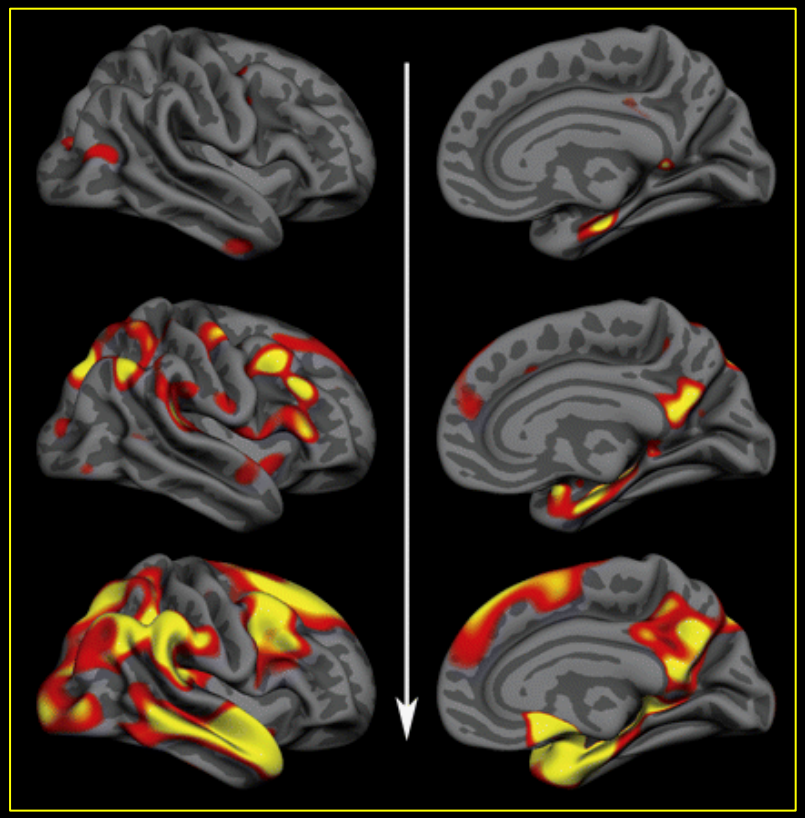

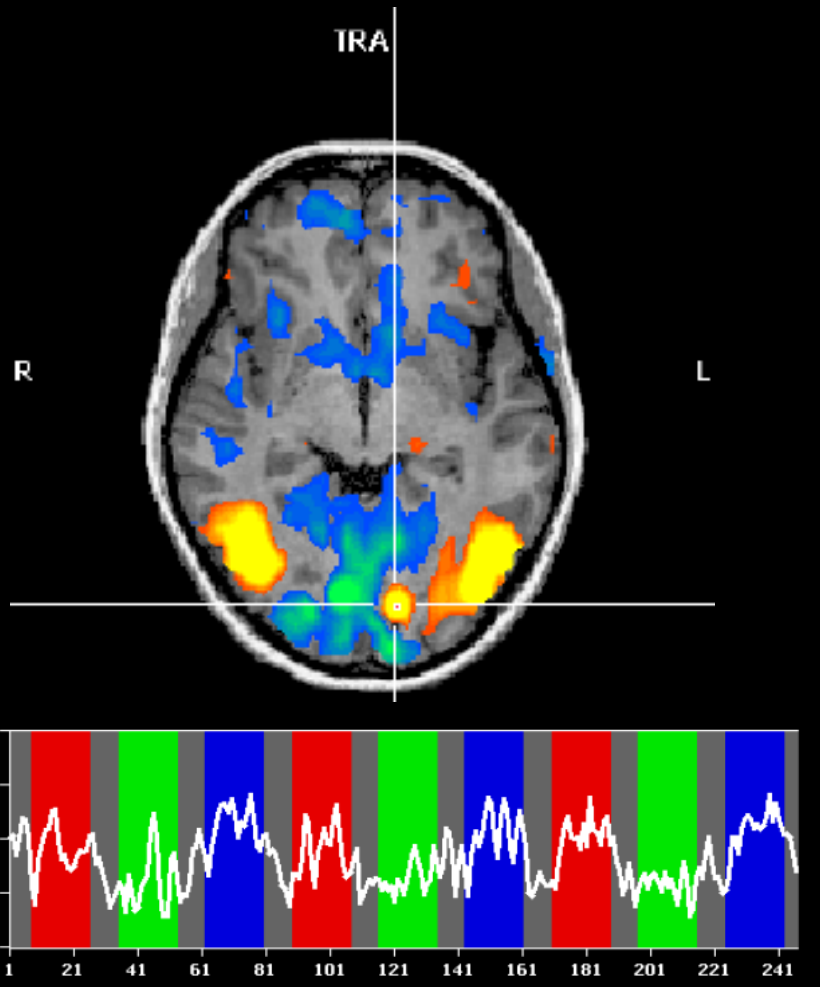

3D

Spessore corticale

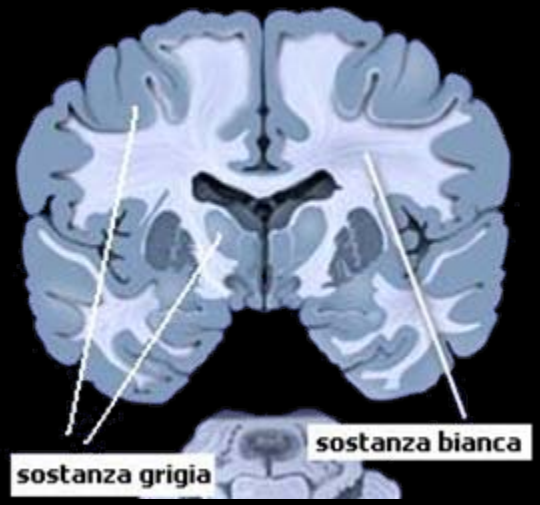

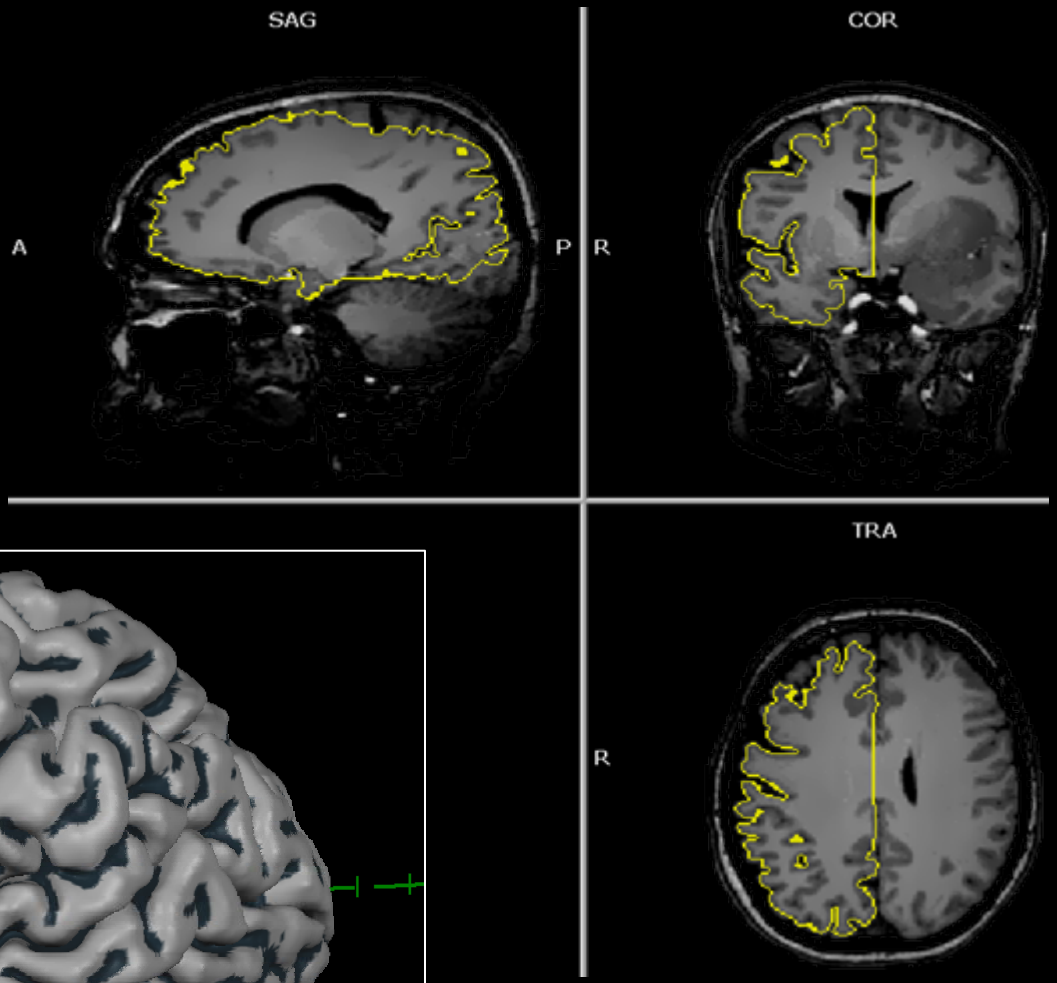

Segmentazione semi-automatica

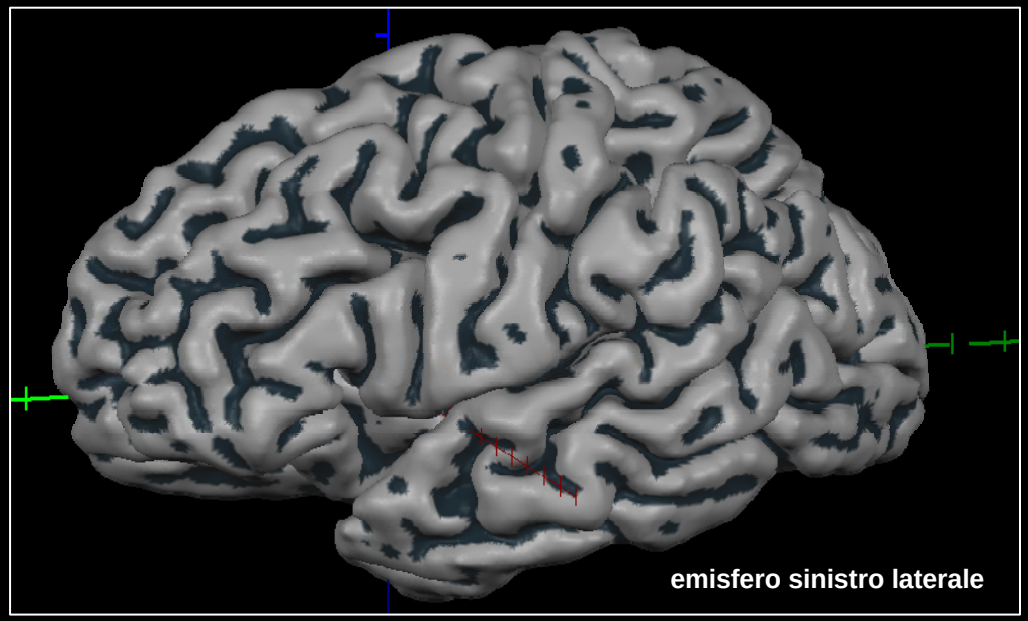

Ricostruzione 3D della materia cerebrale

RICOSTRUZIONE 3D

- Materia grigia cerebrale



- Visibili giri e solchi cerebrali

“rigonfiamento”

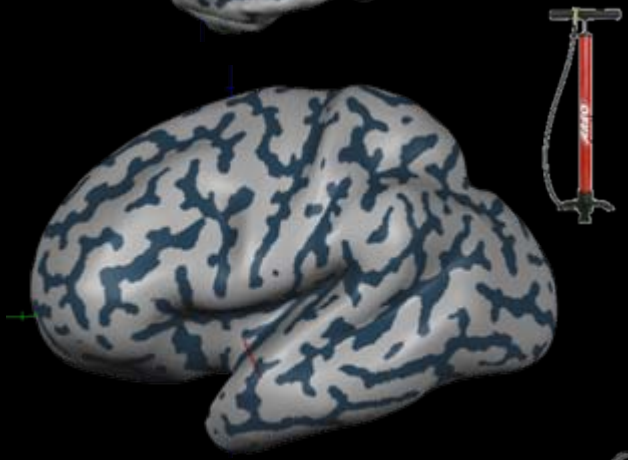

- Visibili i lobi cerebrali

“appiattimento”

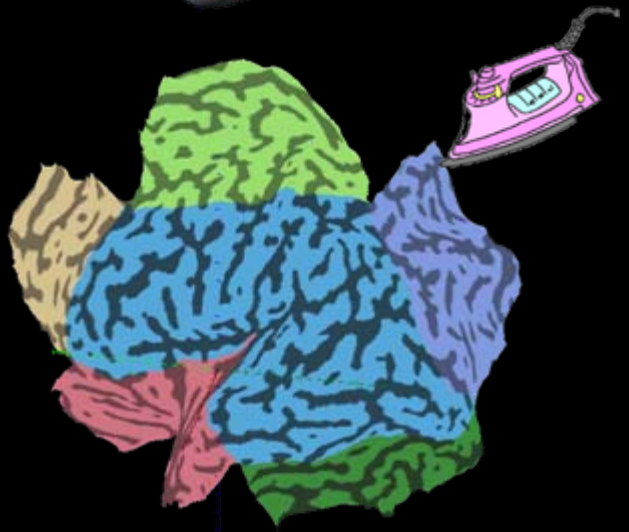

Attivazione funzionale & “Cortical Thickness”

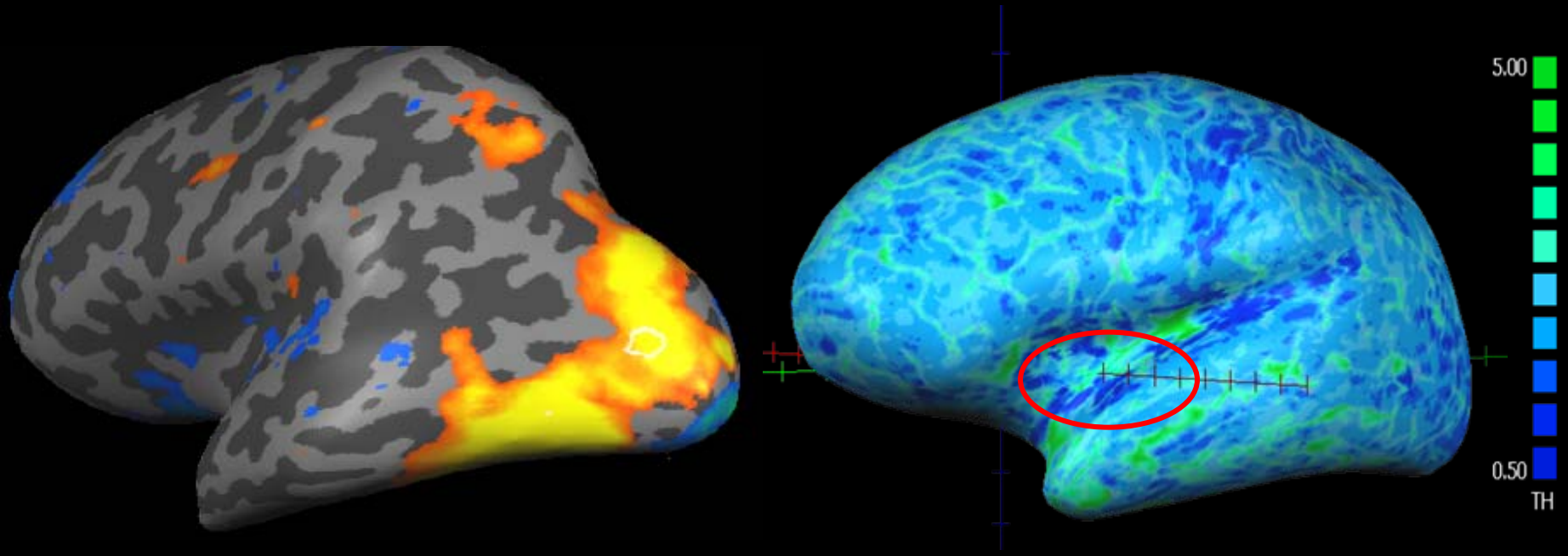

- mappa colorimetrica in volumi o millisec.
- risposta fisiologica (emodinamica)
- giallo/arancione: aree max attivazione
- blu: aree deattivate

- mappa colorimetrica in millimetri
- risposta quantitativa
- verde: + 5mm **maggiore** s.c.
- blu: 0.50 mm **minor** s.c. ATROFIA

marijuana
s.c. < aree temporo-mesiali

Tensore di diffusione

DTI

- metodica non invasiva
- diffusione delle molecole di H_2O
- misura la connettività anatomica
- posizione e morfologia fasci fibra

Associa a ogni punto dello spazio un **tensore**, ossia una matrice di dati con parametri d'orientamento per ciascuna posizione dello spazio

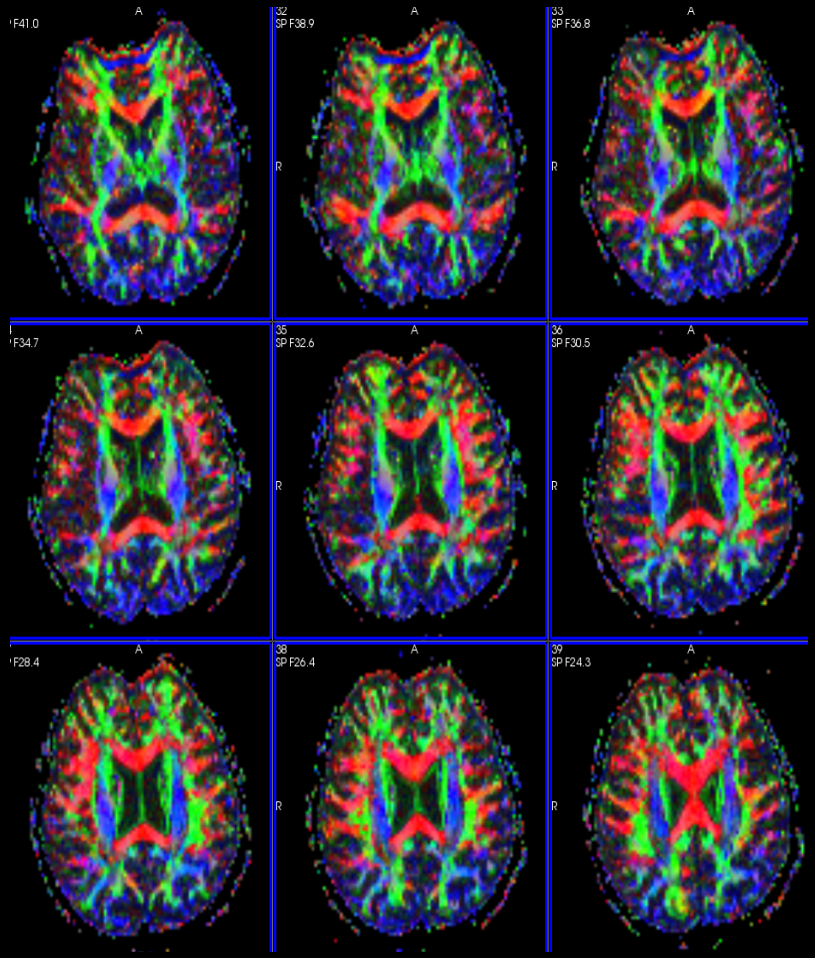

Tensore di diffusione

DTI

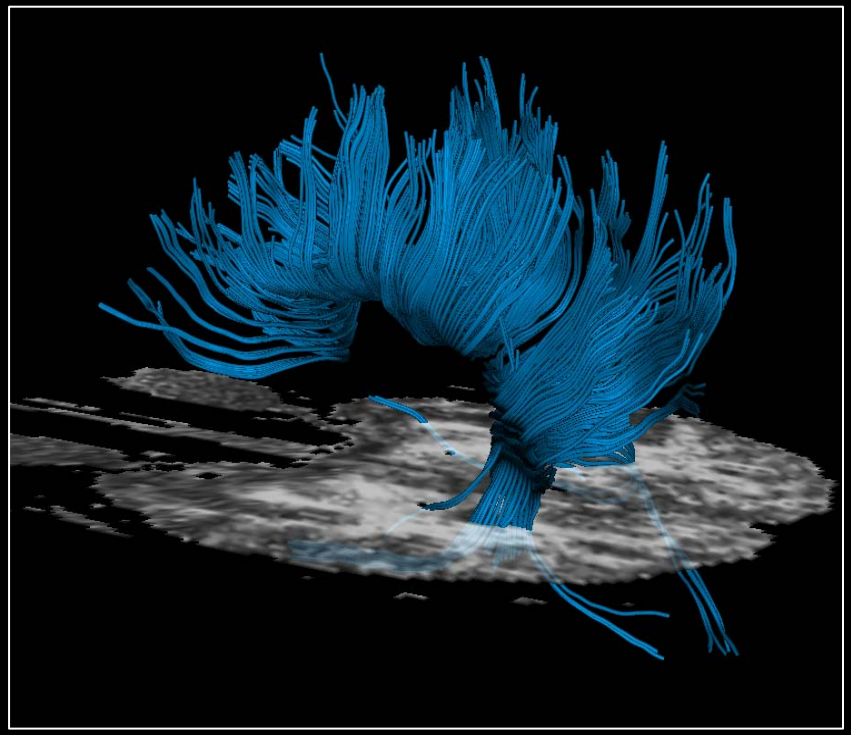

Fasci di fibra del corpo calloso

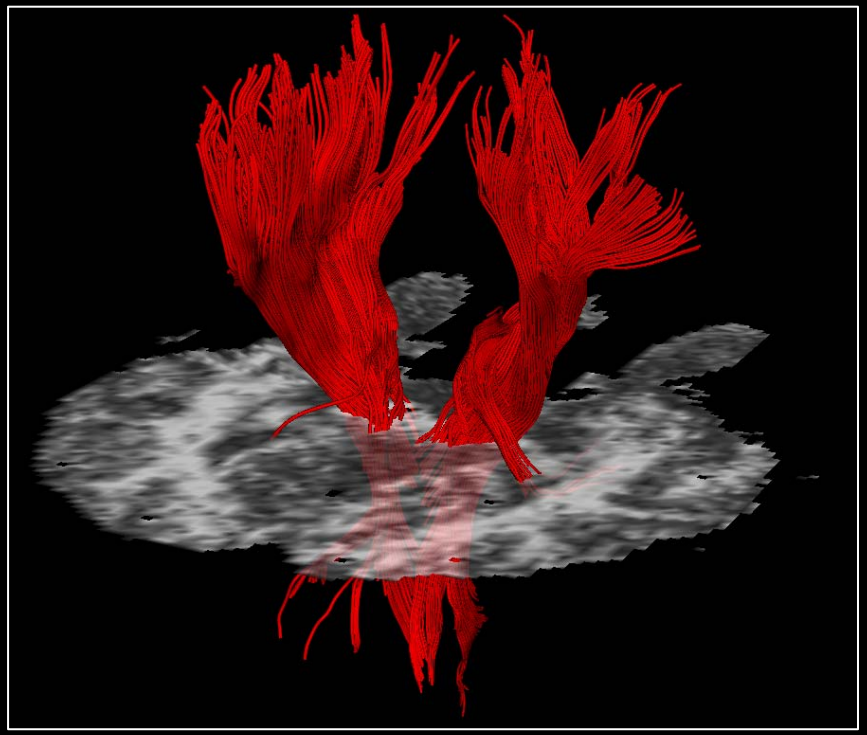

Fasci corticospinali

normale o alterata integrità della sostanza bianca cerebrale

Conclusioni

- Importanza del Neuroimaging (integrato)
- Ampia possibilità di sviluppo futuro
- Nuove sequenze per studio morfologia e funzione
- Supporto dei dati clinici
- Multidisciplinarietà (biochimica, fisica, etc..)

